

# HER3-Directed ADCs in the Treatment of EGFR-Mutated Advanced or Metastatic NSCLC Progressing on TKI and Platinum-Based Chemotherapy

Pasi A. Jänne, MD, PhD

Helena A. Yu, MD



## 56-YEAR-OLD MAN

### Case Description:

- Presented with chest pain and shortness of breath
- CT imaging demonstrated LUL lung mass and metastases to the pleura, mediastinal lymph nodes, right adrenal gland, and several bone lesions
- Biopsy demonstrated an *EGFR* exon 19 deletion mutation
- He began single-agent osimertinib and had rapid symptomatic improvement and an excellent radiographic response that lasted 15 months
- Progressive liver lesions were found on restaging scans
- Repeat biopsy showed the original *EGFR* exon 19 deletion mutation but no other new genomic alterations
- Carboplatin/pemetrexed was added to osimertinib
- After 2 cycles of chemotherapy, repeat imaging demonstrated a reduction in his liver disease; no new sites of disease were noted
- Following 4 cycles of combination therapy, the patient was switched to maintenance pemetrexed and osimertinib
- After 6 cycles of maintenance pemetrexed/osimertinib, the liver lesions had started to grow; new left-sided adrenal mass was also noted

**If all options were available, which one would you consider as the next line of treatment?**

## 56-YEAR-OLD MAN

### Case Description:

- Presented with chest pain and shortness of breath
- CT imaging demonstrated LUL lung mass and metastases to the pleura, mediastinal lymph nodes, right adrenal gland, and several bone lesions
- Biopsy demonstrated an *EGFR* exon 19 deletion mutation
- He began single-agent osimertinib and had rapid symptomatic improvement and an excellent radiographic response that lasted 15 months
- Progressive liver lesions were found on restaging scans
- Repeat biopsy showed the original *EGFR* exon 19 deletion mutation but no other new genomic alterations
- Carboplatin/pemetrexed was added to osimertinib
- After 2 cycles of chemotherapy, repeat imaging demonstrated a reduction in his liver disease; no new sites of disease were noted
- Following 4 cycles of combination therapy, the patient was switched to maintenance pemetrexed and osimertinib
- After 6 cycles of maintenance pemetrexed/osimertinib, the liver lesions had started to grow; new left-sided adrenal mass was also noted

**If all options were available, which one would you consider as the next line of treatment?**

“

***We know from the press release that [HERTHENA-Lung02] met its primary endpoint of PFS prolongation in patients who were treated with patritumab deruxtecan.***

”

PASI JÄNNE, MD, PhD

## 46-YEAR-OLD WOMAN

### Case Description:

- Initially presented with *EGFR* exon 19 deletion-positive lung adenocarcinoma with metastases to lung, lymph node, brain, and bone
- She started treatment with osimertinib and had an excellent partial response to therapy for 16 months
- She had disease progression in her lung and new bone metastases; started on carboplatin/pemetrexed and continued osimertinib
- She received 4 cycles followed by 4 months of pemetrexed maintenance until she had evidence of progression of disease with growing lung nodules and new liver metastases
- Started treatment with HER3-DXd
- First cycle went well with no problems during the infusion, but she had significant nausea that limited food/liquid intake the first week
- She presented for C2D1 and her ANC was 0.9, total WBC was 2.0, platelets were 95, and hemoglobin was 12.7

**What medications or premeds would help with nausea?**

## 46-YEAR-OLD WOMAN

### Case Description:

- Initially presented with *EGFR* exon 19 deletion-positive lung adenocarcinoma with metastases to lung, lymph node, brain, and bone
- She started treatment with osimertinib and had an excellent partial response to therapy for 16 months
- She had disease progression in her lung and new bone metastases; started on carboplatin/pemetrexed and continued osimertinib
- She received 4 cycles followed by 4 months of pemetrexed maintenance until she had evidence of progression of disease with growing lung nodules and new liver metastases
- Started treatment with HER3-DXd
- First cycle went well with no problems during the infusion, but she had significant nausea that limited food/liquid intake the first week
- She presented for C2D1 and her ANC was 0.9, total WBC was 2.0, platelets were 95, and hemoglobin was 12.7

**Should treatment proceed, and what can be done to prevent cytopenias from occurring in the future?**

“

***In the clinical trials, these cytopenias [from HER3-DXd] weren't associated with any kind of clinical complications like bleeding or neutropenic fever, and they do seem to be front-loaded with the first few cycles.***

”

HELENA YU, MD

“

*Hopefully with patritumab deruxtecan soon to be approved, I would definitely think about utilizing that in this third-line setting.*

”

HELENA YU, MD



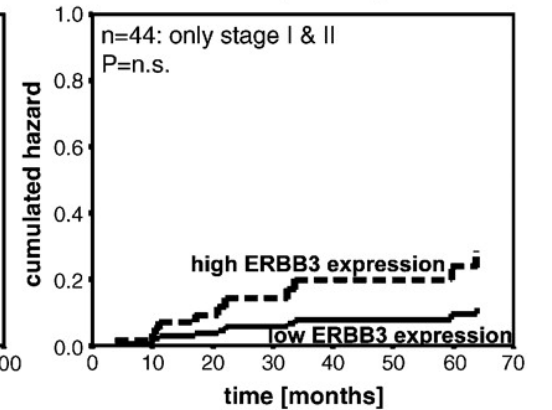
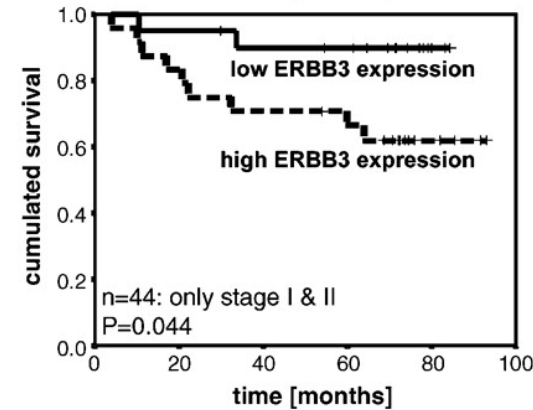
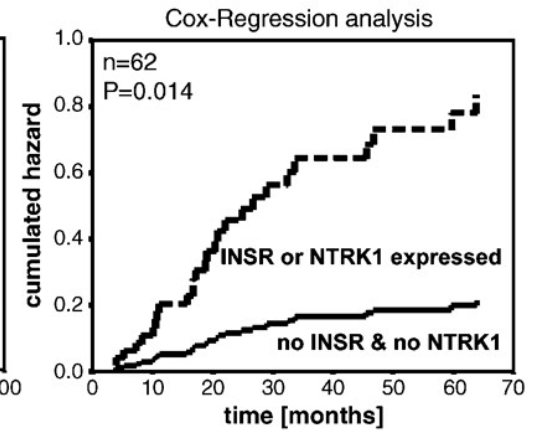
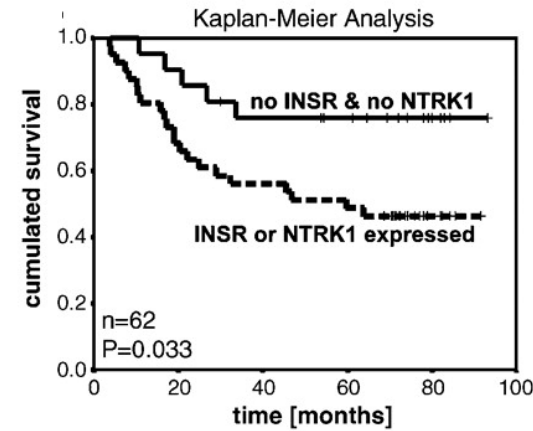
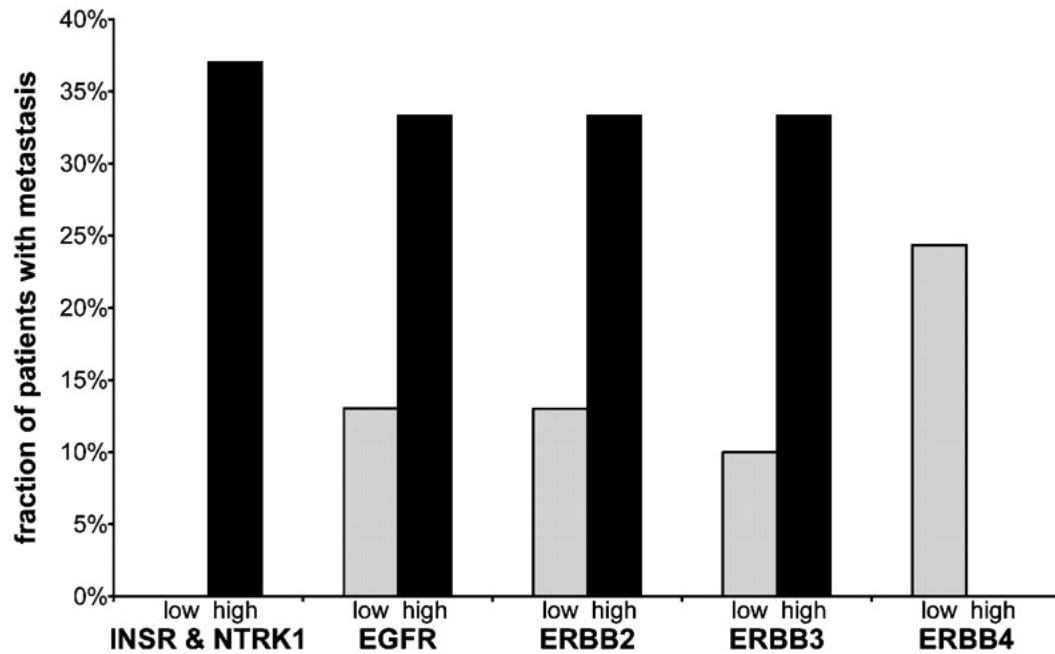
“

***I certainly think there is a role for HER3-directed ADCs like patritumab deruxtecan in this space, following EGFR TKI and chemotherapy treatment.***

”

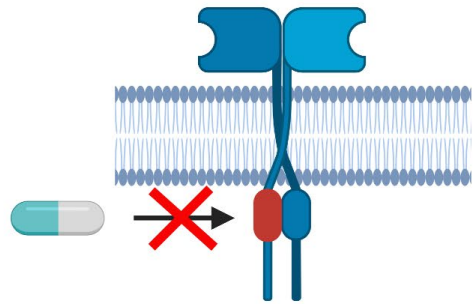
PASI JÄNNE, MD, PhD

# Association of HER3 Expression, Metastases, and Survival in NSCLC



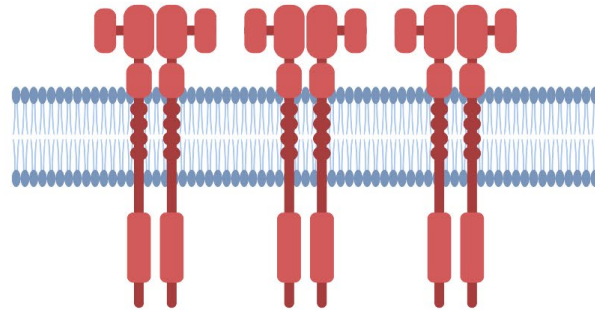
# Mechanisms of Acquired Resistance to Kinase Inhibitors in Lung Cancer

Mutations in the Drug Target



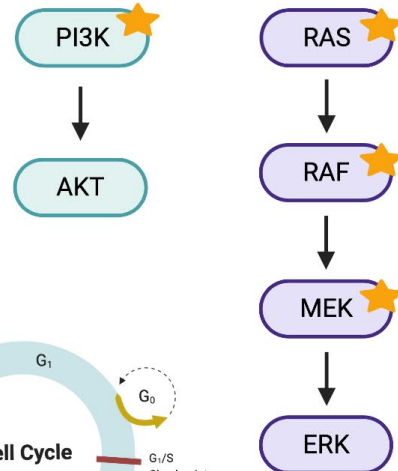
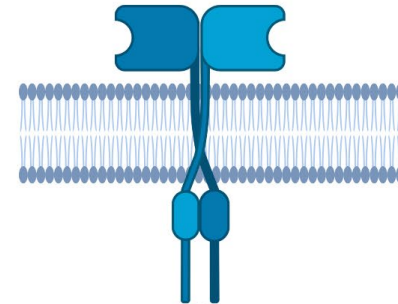
Impact Drug Binding

Bypass Signaling

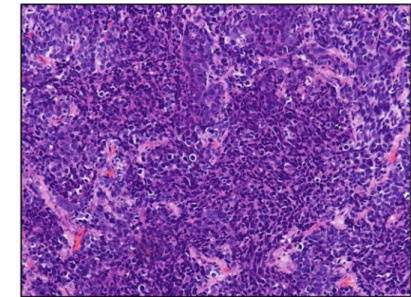


Oncogene Amplification

Mutations in Downstream Effectors

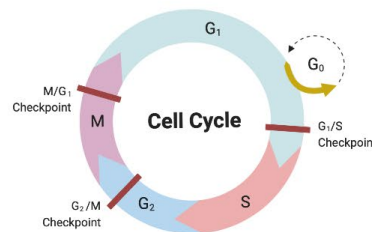


State Transformation

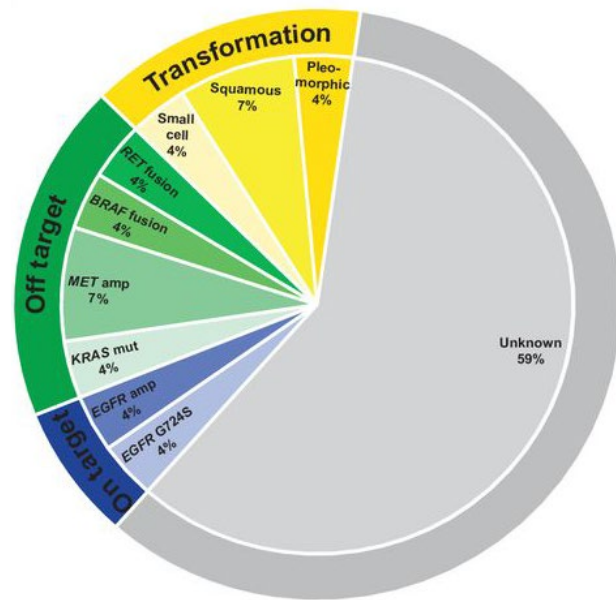


Small Cell Lung cancer  
Squamous Cell Lung Cancer

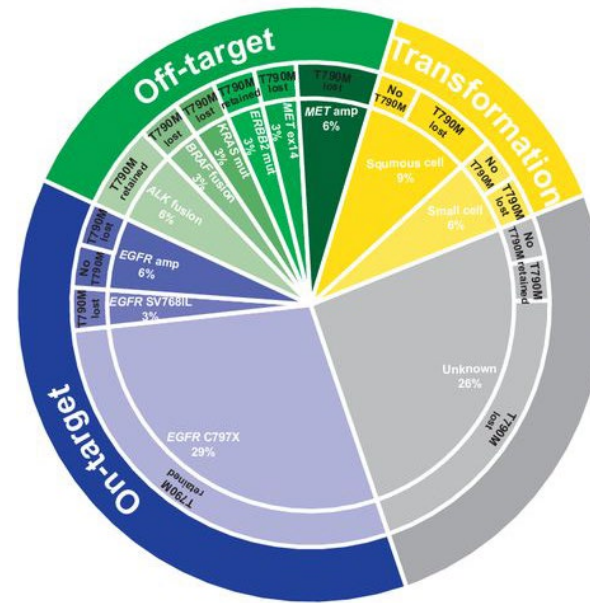
Oncogene Rearrangement



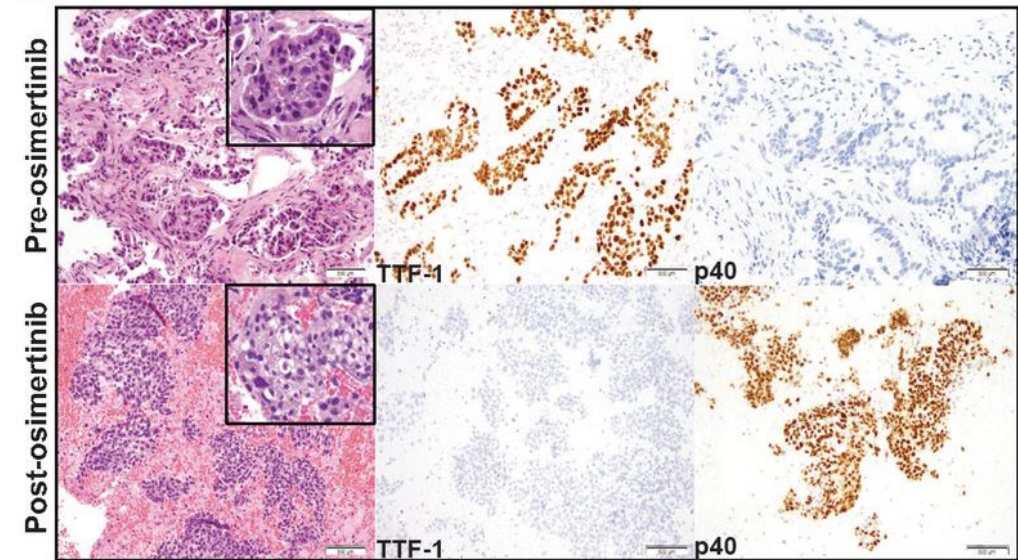
# Acquired Resistance Mechanisms to Osimertinib From Tissue-Based Studies



First-Line Therapy



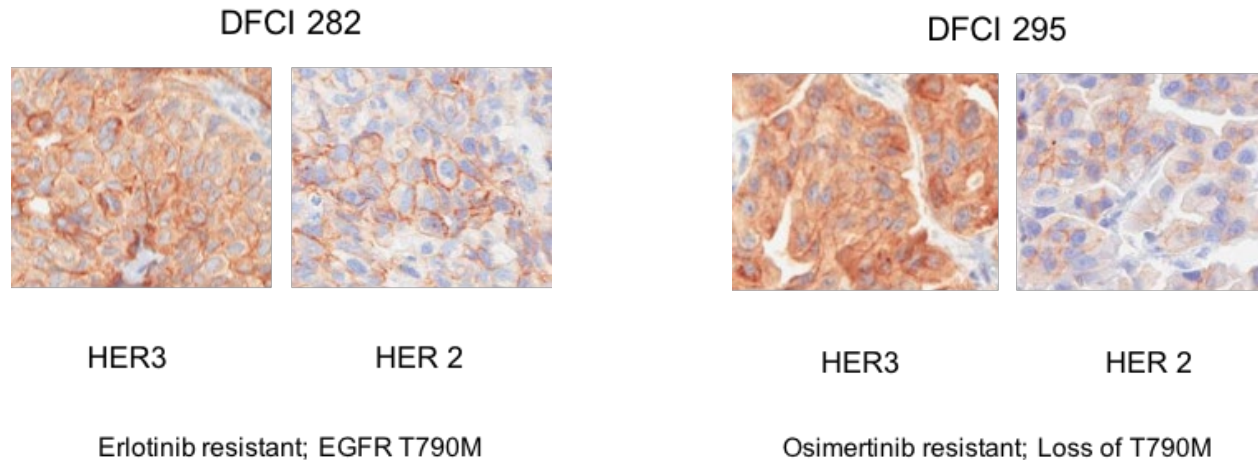
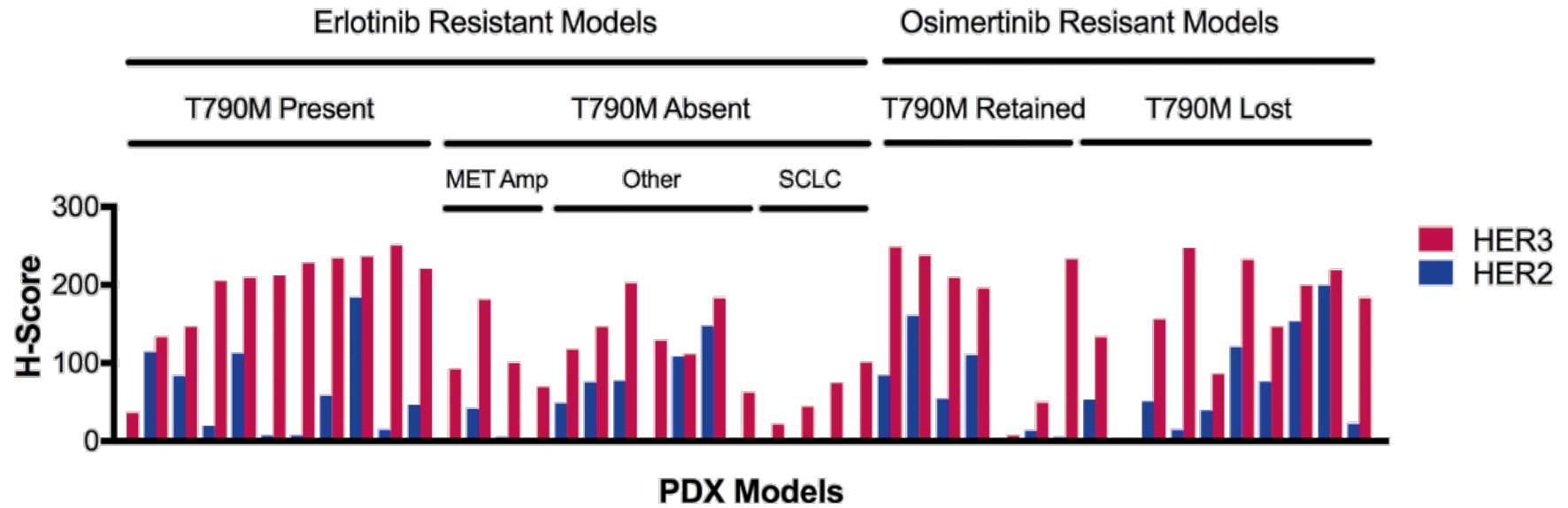
Later-Line Therapy



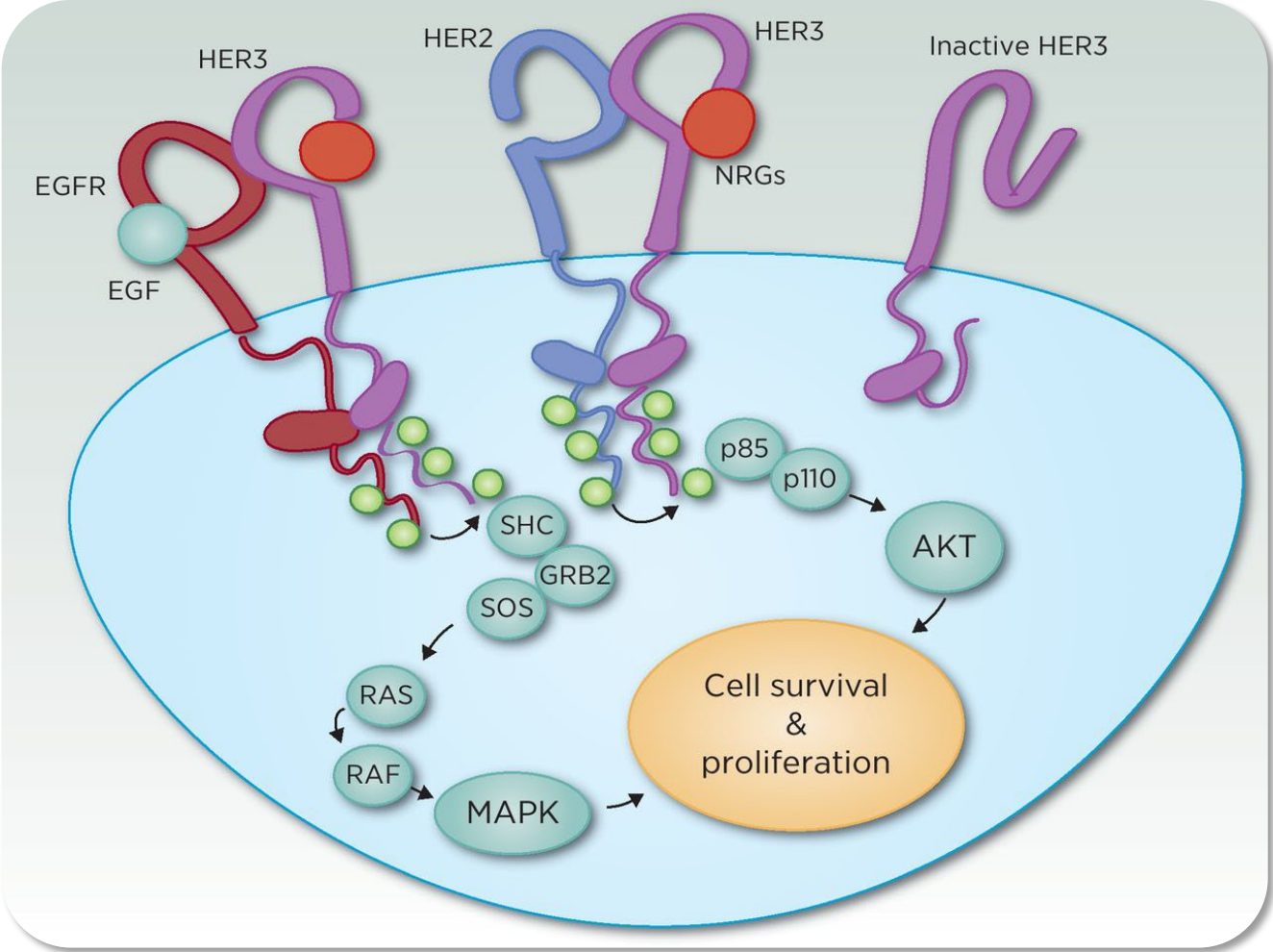
Squamous Cell Transformation



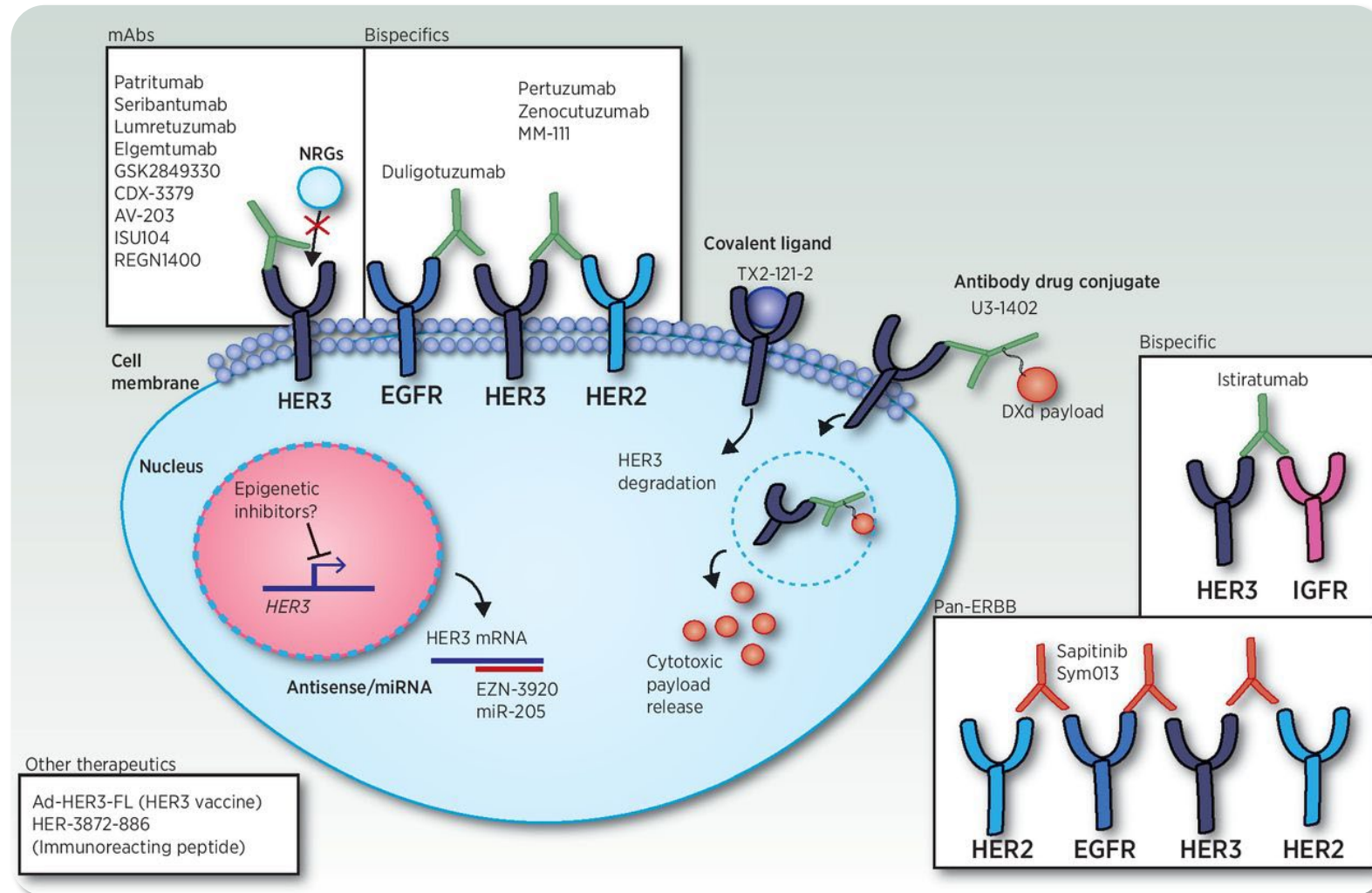
# HER3 and HER2 Expression Are Common in EGFR-Mutant Drug-Resistant Patient-Derived Xenograft Models



# HER3 Forms Heterodimers Upon Ligand Activation



# Therapeutic Strategies to Inhibit HER3



# HERTHENA-Lung01: Study Design

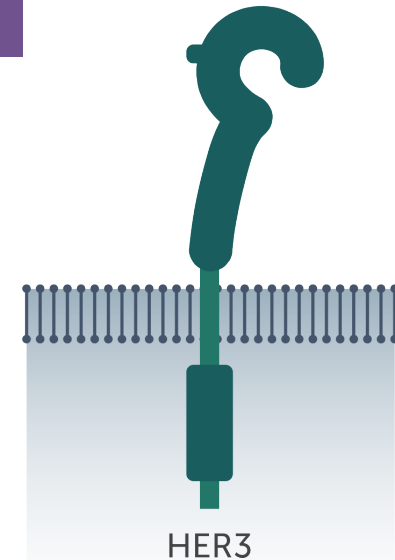
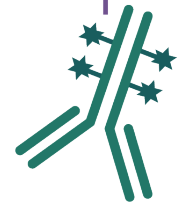
Patients with advanced progressive **EGFR-mutant** NSCLC;  
prior treatment with **platinum-based chemotherapy** and **osimertinib**



**Patritumab Deruxtecan**  
5.6 mg/kg IV Q3W  
(n = 226)

- **Primary endpoint:** ORR by BICR
- **Key secondary endpoint:** DoR by BICR

Anti-HER3 ADC  
Patritumab deruxtecan

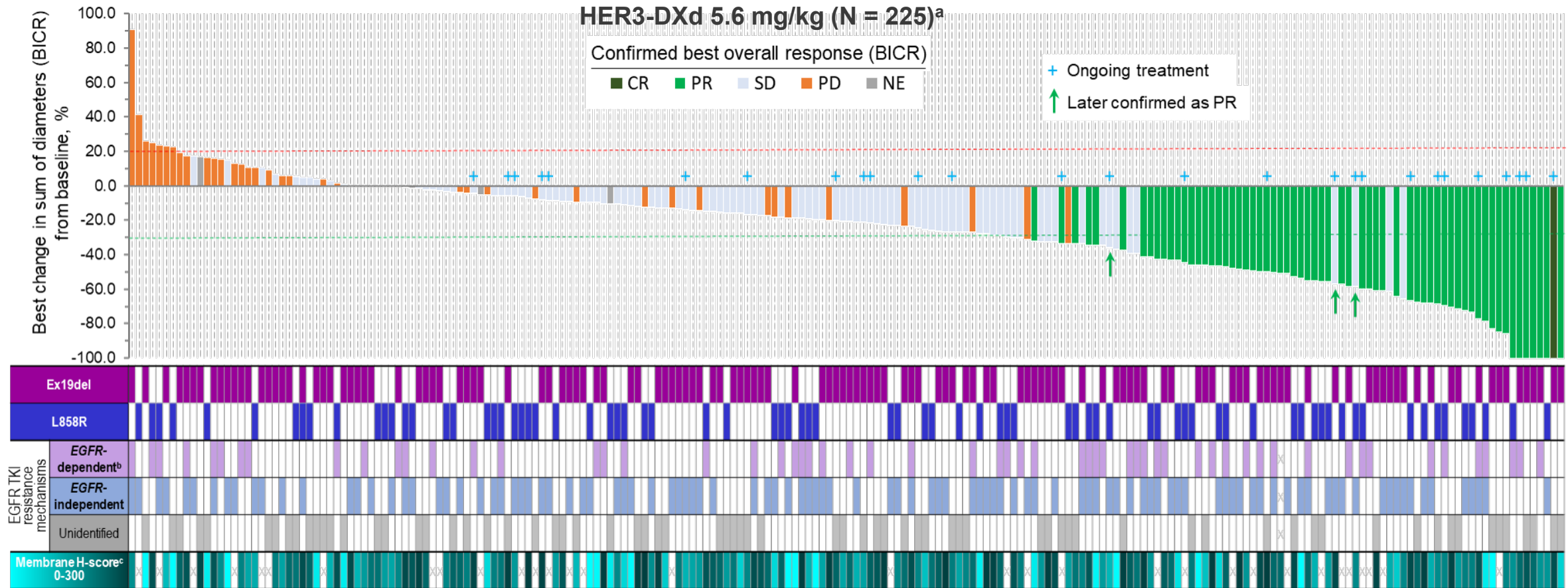




# HERTHENA-Lung01: Overall Efficacy

Efficacy Outcome	All Patients (n = 225)	Patients Who Received Osimertinib (n = 209)
Confirmed ORR, %	29.8	29.2
Median PFS, mo	5.5	5.5
Median OS, mo	11.9	11.9

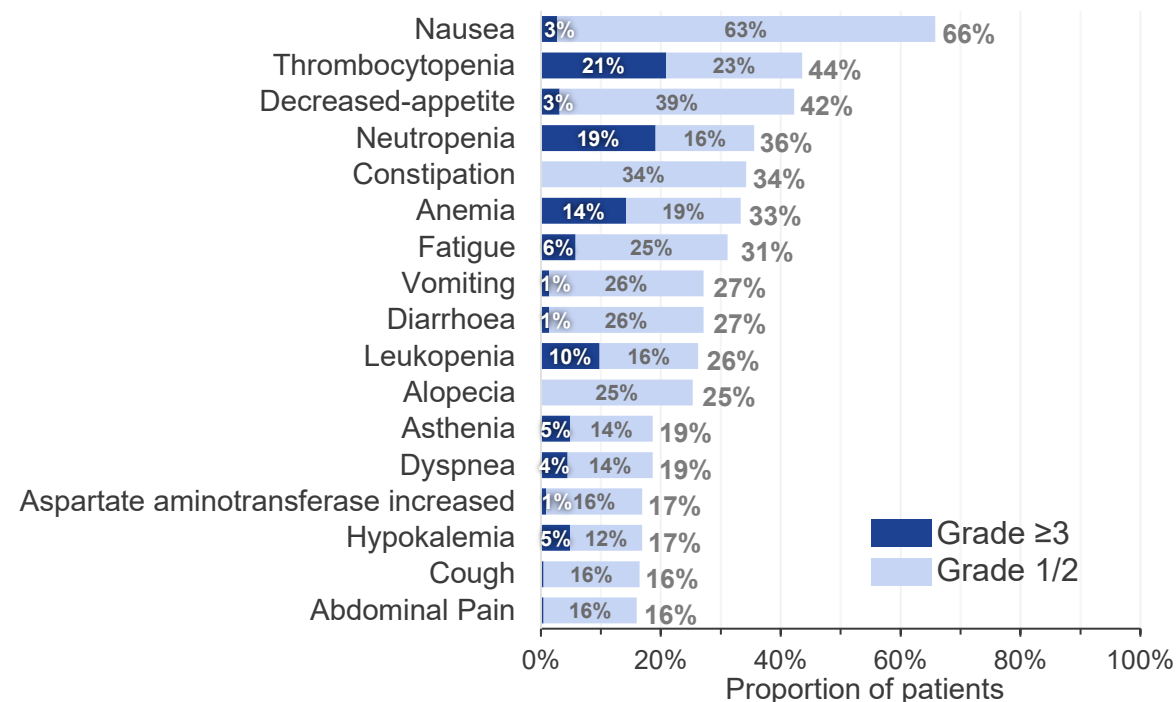
# HERTHENA-Lung01: Antitumor Activity Across EGFR TKI Resistance Mechanisms



# HERTHENA-Lung01: Safety

Safety summary	HER3-DXd 5.6 mg/kg (N = 225)
Any TEAE, n (%)	224 (99.6)
Associated with treatment discontinuation	16 (7.1)
Associated with treatment dose reduction	48 (21.3)
Associated with treatment dose interruption	91 (40.4)
Associated with death	24 (10.7)
Grade ≥3 TEAE, n (%)	146 (64.9)
Treatment-related TEAE, n (%)	215 (95.6)
Associated with death	4 (1.8)
Grade ≥3	102 (45.3)
Serious TEAE	34 (15.1)
Adjudicated interstitial lung disease, n (%) [All were adjudicated as treatment-related]	12 (5.3)
Grade 1	1 (0.4)
Grade 2	8 (3.6)
Grade 3	2 (0.9)
Grade 4	0
Grade 5	1 (0.4)

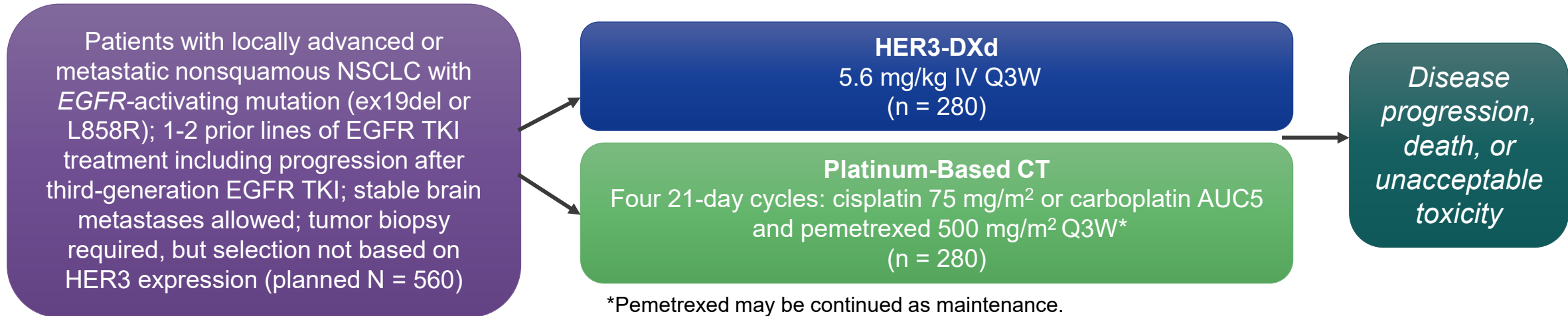
## Most Common Grade ≥3 TEAEs Occurring in ≥3% of Patients (N = 225)



# HERTHENA-Lung01: CNS Efficacy

CNS Response	Patients With Baseline Brain Mets and No RT (n = 30)
CNS confirmed ORR, n (%)	10 (33.3)
CNS DCR, %	76.7
Median CNS DoR, mo	8.4

# HERTHENA-Lung02: Phase 3 Study of HER3-DXd in EGFR-Mutated NSCLC



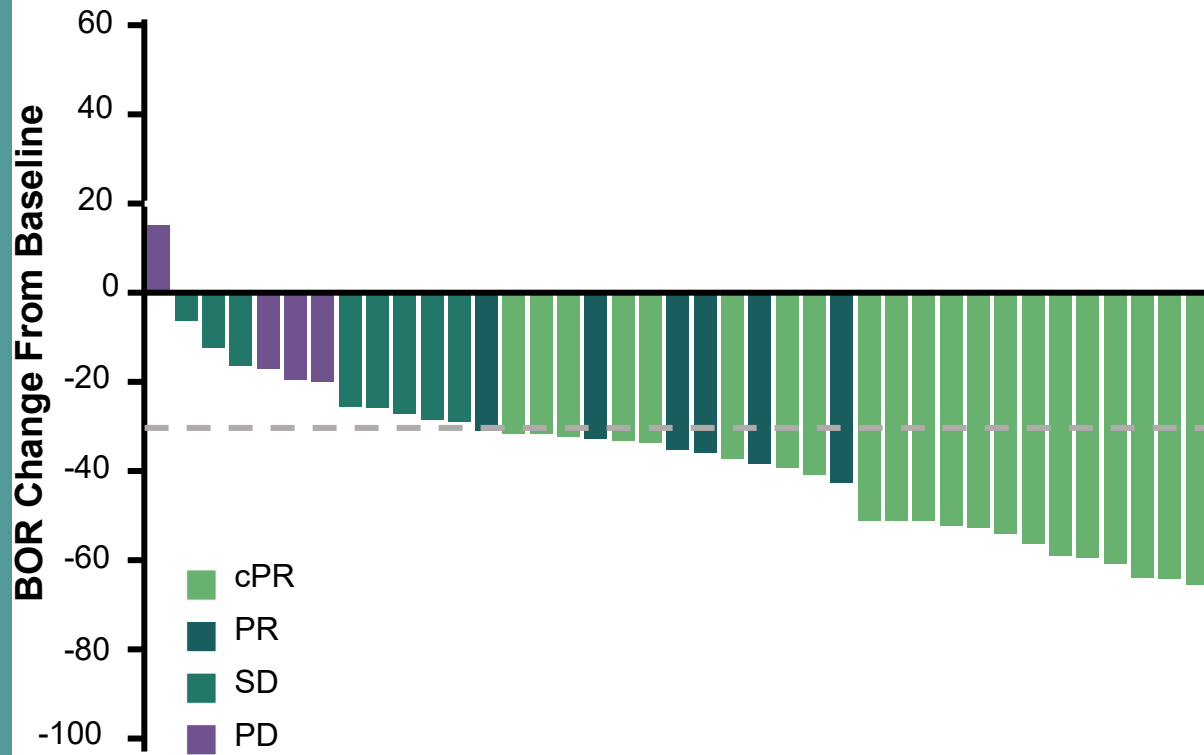
- **Primary endpoint:** PFS by BICR (RECIST v1.1)
- **Secondary endpoints:** PFS by investigator, OS, ORR, DoR, DCR, TTR, safety

**According to a press release on 9/17/2024, HERTHENA-Lung02 met its primary endpoint of PFS.**

# BL-B01D1: Response Rates in *EGFR*-Mutated NSCLC

- All patients in the current analysis received Q3W dose regimens

***EGFR*-Mutated NSCLC (N = 40)**



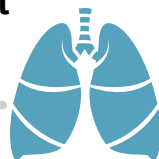	<i>EGFR</i> -Mutated NSCLC		<i>EGFR</i> Wild-Type NSCLC	
	All (n = 40)	Treated/No CNS Mets (n = 13)	All (n = 62)	2L Post PBC (n = 26)
Prior CT lines, %				
• 0	25	8	0	0
• 1	50	46	42	100
• 2+	25	46	56	0
ORR, %	67.5	69.2	40.3	50.0
cORR, %	52.5	61.5	30.6	38.5
DCR, %	87.5	92.3	87.1	80.8
mDoR, mo	8.5	12.3	NR	NR
mPFS, mo	5.6	15.0	5.4	6.7

# Management of ILD Associated With HER3-DXd

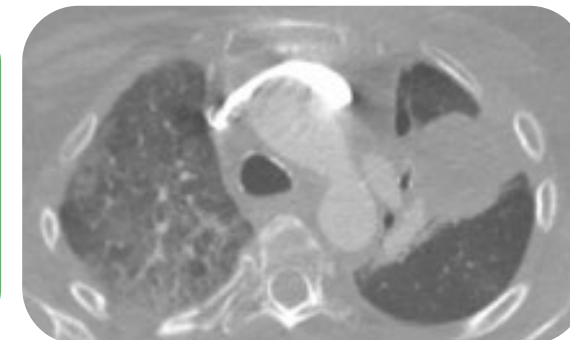


## What to Look for

- Shortness of breath, particularly on exertion
- Dry cough
- Chest discomfort
- Fatigue



Promptly investigate any evidence of suspected ILD/pneumonitis with high-resolution CT, pulmonologist consult, and blood cultures/CBC



Grade and Description	Protocol Management Recommendations
1: Asymptomatic; clinical or diagnostic observations only	<ul style="list-style-type: none"> <li>▪ Hold patritumab deruxtecan until resolution to grade 0                             <ul style="list-style-type: none"> <li>▪ If AE resolves in <math>\leq 28</math> days, resume with same dose of patritumab deruxtecan</li> <li>▪ If AE resolves in <math>&gt; 28</math> days, resume with reduced dose of patritumab deruxtecan</li> </ul> </li> <li>▪ Consider corticosteroid treatment (eg, prednisone <math>\geq 0.5</math> mg/kg/day)</li> </ul>
2: Symptomatic; limiting instrumental ADL 3: Severe symptoms; limiting self-care ADL or life-threatening respiratory compromise	<ul style="list-style-type: none"> <li>▪ <b>Permanently discontinue patritumab deruxtecan</b></li> <li>▪ Promptly initiate corticosteroid treatment (eg, <math>\geq 1</math> mg/kg/day prednisolone or equivalent) and continue for <math>\geq 14</math> days followed by gradual taper for <math>\geq 4</math> weeks</li> </ul>
<b>For all grades</b>	<ul style="list-style-type: none"> <li>▪ Oxygen supplementation for hypoxia</li> <li>▪ Monitor closely for worsening symptoms, re-image as clinically indicated</li> <li>▪ Supportive treatment for prolonged corticosteroid use</li> <li>▪ Consider infliximab, mycophenolate mofetil, IVIG, etc., if corticosteroid refractory</li> </ul>

**Dose reductions: Starting Dose 5.6 mg/kg Q3W → Reduction 1: 4.8 mg/kg → Reduction 2: 3.2 mg/kg → Discontinue**

“

***Patients that had higher-grade pneumonitis with symptoms, even if they resolved with treatment, were not allowed to be re-treated.***

”

PASI JÄNNE, MD